

Comparison of Endodontic Diagnosis and Treatment Planning Decisions Using Cone-beam Volumetric Tomography versus Periapical Radiography

Jonathan Ee, BDS, DDS, MS, FRCD(C),* Mobamed I. Fayad, DDS, MS, PhD,[†]
and Bradford R. Johnson, DDS, MHPE[‡]

Abstract

Introduction: Accurate and confident treatment planning is an essential part of endodontic practice. Periapical radiographs have been used to aid in the diagnosis of pathology and to help establish an appropriate treatment strategy. Recently, a new imaging modality, cone-beam volumetric tomographic (CBVT) imaging, has been shown to be a useful tool in a number of endodontic applications. The aim of this study was to compare the relative value of preoperative periapical radiographs and CBVT scanning in the decision-making process in endodontic treatment planning. **Methods:** Thirty endodontic cases completed in a private endodontic practice were randomly selected to be included in this study. Each case was required to have a preoperative digital periapical radiograph and a CBVT scan. Three board-certified endodontists reviewed the 30 preoperative periapical radiographs. Two weeks later, the CBVT volumes were reviewed in random order by the same evaluators. The evaluators were asked to select a preliminary diagnosis and treatment plan based solely on their interpretation of the periapical and CBVT images. Diagnosis and treatment planning choices were then compared to determine if there was a change from the periapical radiograph to the CBVT scan. **Results:** A difference in treatment plan between the 2 imaging modalities was recorded in 19 of 30 cases (63.3%, $P = .001$), 17 of 30 cases (56.6%, $P = .012$), and 20 of 30 cases (66.7%, $P = .008$) for examiners 1, 2, and 3, respectively. **Conclusions:** Under the conditions of this study, preoperative CBVT imaging provides additional information when compared with preoperative periapical radiographs, which may lead to treatment plan modifications in approximately 62% of the cases. (*J Endod* 2014; ■:1–7)

Key Words

Clinical decision making, cone-beam computed tomography, cone-beam volumetric tomography

In endodontics, clinical examination and diagnostic imaging are both essential components of the preoperative diagnosis (1). Accurate diagnostic imaging supports the clinical diagnosis and allows the clinician to better visualize the area in question. Conventional 2-dimensional (2D) radiographs provide a cost-effective, high-resolution image, which continues to be the most popular method of imaging today. However, the diagnostic potential of periapical radiographs is limited. Information may be difficult to interpret, especially when the anatomy and background pattern are complex (2).

Cone-beam volumetric tomographic (CBVT) imaging is a diagnostic imaging modality that provides a 3-dimensional (3D) image of the maxillofacial region. The term *CBVT*, as used in this study, is synonymous with cone-beam computed tomographic imaging. CBVT scanning is capable of providing images at a low radiation dose and with sufficient spatial resolution for applications in endodontic diagnosis and treatment planning. Furthermore, CBVT imaging overcomes many limitations with conventional radiography such as early detection of invasive cervical resorption lesions, vertical root fractures, and 3D evaluation of the root canal space and surrounding anatomy (3–10). Diagnostic information directly influences treatment planning and clinical decisions. Accurate data lead to better treatment decisions and potentially more predictable outcomes (11).

Although conventional periapical radiography has been used for many years as a diagnostic aid in endodontics, some studies now show the inferiority of periapical radiographs in detecting pathology when compared with CBVT imaging (12–16). CBVT scanning has been successfully used in endodontics, and several recent studies have shown the advantages of CBVT imaging over periapical radiographs (17–21). However, research to support the position that information obtained from a CBVT scan has an actual impact on treatment planning is currently unavailable.

There has been considerable debate regarding whether or not CBVT imaging should be used as a standard preoperative imaging modality in endodontics. The primary argument against routine preoperative CBVT imaging before endodontic therapy relates to the additional ionizing radiation. The effective radiation dose to patients when using CBVT imaging is higher than conventional 2D radiography, and, therefore, the benefit to the patient must outweigh any potential risks of the additional radiation exposure. Radiation dose should be kept as low as reasonably achievable (22, 23). The value of CBVT imaging for endodontic diagnosis and treatment planning should be determined on an individual basis to ensure that the risk/benefit assessment supports its use. CBVT imaging should not be used to simply verify what is already known to be present but rather to help visualize unknown

From the *Private Practice, Mississauga, Ontario, Canada; and [†]Department of Endodontics, University of Illinois at Chicago, Chicago, Illinois.

Address requests for reprints to Dr Bradford R. Johnson, Department of Endodontics (MC 642), University of Illinois at Chicago, 801 S Paulina Street, Chicago, IL 60612. E-mail address: bjohnson@uic.edu
0099-2399/\$ - see front matter

Copyright © 2014 American Association of Endodontists.
<http://dx.doi.org/10.1016/j.joen.2014.03.002>

Clinical Research

anatomy and suspected pathology. The value of CBVT scanning in treatment planning has not been investigated. Therefore, it is important to determine if the information gained by CBVT imaging may alter a clinician's treatment plan. The purpose of this study was to investigate whether viewing a preoperative CBVT scan could significantly change treatment decisions compared with decisions reached by viewing 2D preoperative periapical radiographs only. The null hypothesis was that there would be no difference in treatment decisions when using periapical radiographs only compared with a CBVT scan.

Materials and Methods

Case Selection

Institutional review board approval was obtained before the initiation of this retrospective study. A master list of cases completed in a private endodontic practice over a 12-month period in each of the following 6 categories was compiled:

1. Initial treatment
2. Nonsurgical retreatment
3. Periapical surgery
4. Vertical root fracture
5. Internal/external resorption
6. Perforation

Five cases were randomly selected from each category. Figures 1–7 show typical examples of categories 4, 5, and 6. The only inclusion criterion was patients had to be between the ages of 18 and 65 years when presenting to the practice for endodontic consultation or treatment. Pregnant women were excluded. Thirty teeth from 28 different patients were evaluated. Each case included at least 2 angled digital periapical radiographs taken on a Schick CDR intraoral digital sensor (Schick Technologies, Long Island, NY) and a CBVT scan taken with a Kodak 9000 3D (Kodak Carestream Health, Trophy, France). All personal identifiers were removed. The tooth number to be examined was labeled in each radiograph and CBVT scan. Two patients had 2 teeth present in the same radiograph and CBVT scan. The radiographs and CBVT images for these 2 cases were duplicated and placed in random order in the series of 30 cases. Examiners were instructed to examine 1 particular tooth only and to ignore any other pathology seen on the same radiograph or CBVT scan. Although dental history, history of chief complaint, and clinical examination were documented in the patients' records, this information was not disclosed to the 3 examiners. None of the 3 examiners were involved in treatment for any of the patients included in this study to prevent the risk of bias.

Radiographic Diagnosis

Three board-certified endodontists separately reviewed the 30 randomly arranged sets of periapical radiographs. Evaluators were

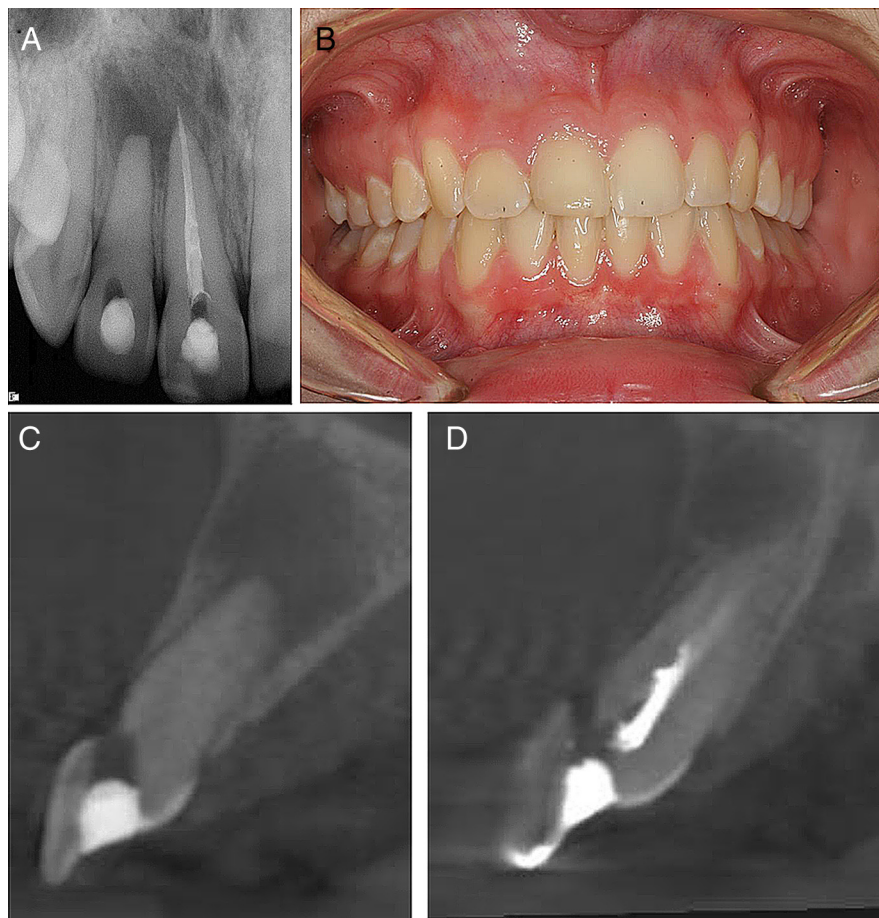


Figure 1. Case 1: (A) A periapical radiograph of teeth #7 and 8. Treatment was initiated on both teeth before referral to an endodontist. Treatment was initiated on both teeth (initial treatment #7 and retreatment attempt on #8). (B) A clinical picture showing normal soft tissue color and architecture. C and D are sagittal CBVT images showing buccal perforations on teeth #7 and 8, respectively.

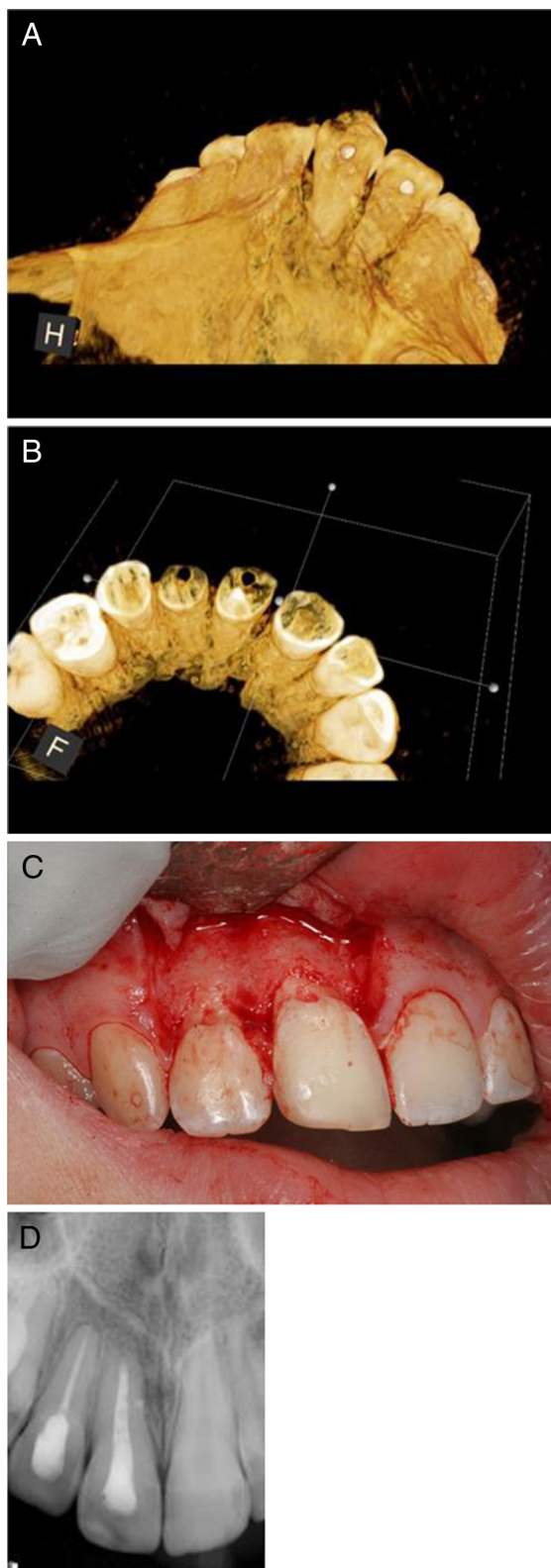


Figure 2. Case 1 continued: *A* and *B* are 3D reconstructions showing the buccal perforations on teeth #7 and 8. *C*) Reflection of a full-thickness mucoperiosteal flap confirmed the presence of perforations on both teeth. The perforations were repaired with Geristore (DenMat, Lompoc, CA). Both teeth were then treated via an orthograde approach with subsequent surgical root-end resection and filling of tooth #8. *D*) One-year recall radiograph showing good healing.

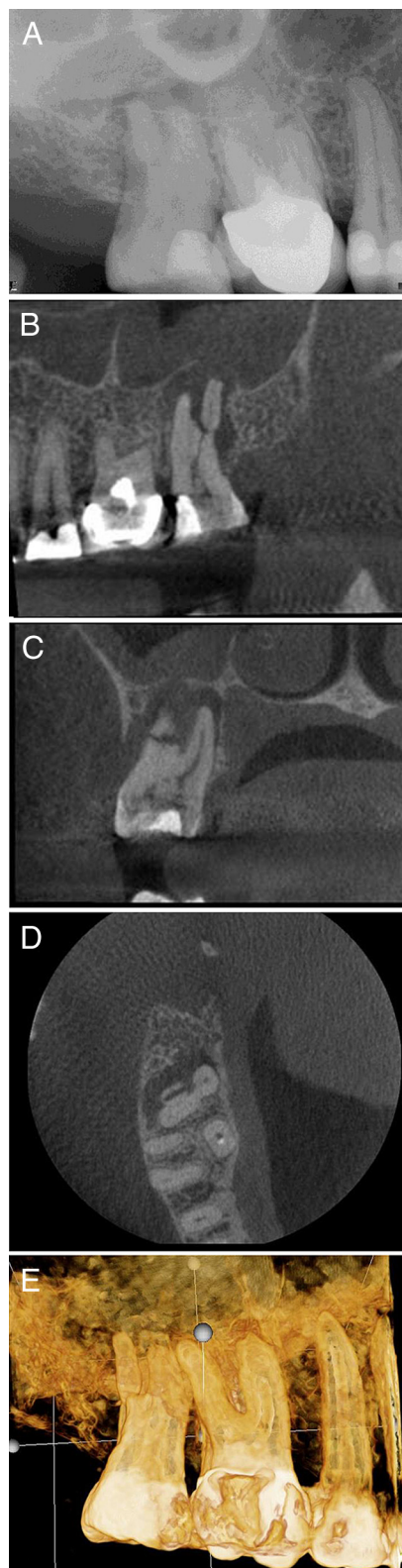


Figure 3. Case 2: *A*) A periapical radiograph of tooth #2. The patient was referred for nonsurgical root canal treatment with a diagnosis of pulp necrosis and asymptomatic apical periodontitis. *B*) A sagittal view showing the distobuccal root fracture. *C*) A coronal view showing the unusual horizontal fracture of the distobuccal root. *D*) An axial view of the apical one third showing a vertical buccopalatal root fracture. *E*) A 3D reconstruction showing the extent of the distobuccal root fracture.

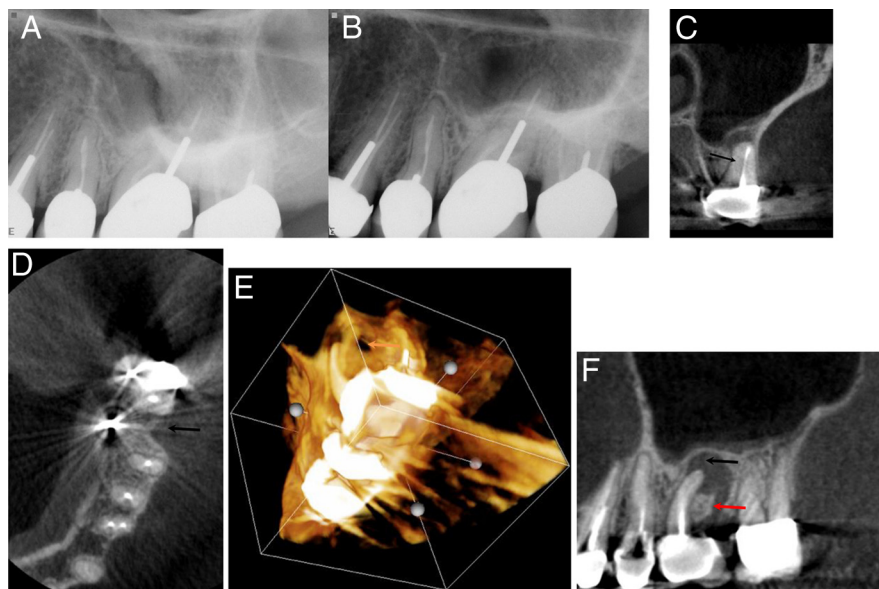


Figure 4. Case 3: this case represents tooth #14. (A and B) Periapical radiographs of tooth #14 mesial and distal angles, respectively. (C) A coronal view of the mesiobuccal root showing a missed mesiobuccal canal (*arrow*). (D) An axial view showing a previous distobuccal root amputation site (*arrow*) that was not obvious on the periapical radiographs. (E) A 3D reconstruction showing a crestal bony defect. (F) A sagittal CBCT view showing the crestal defect (*red arrow*) communicating with the periapical lesion (*black arrow*) and elevating the floor of the maxillary sinus with no evidence of sinus perforation.

asked to select a preoperative diagnosis based on the periapical radiographs only. The list of choices included the following:

1. Periapical radiolucency only
2. Vertical root fracture
3. Internal or external resorption
4. Perforation
5. No radiographic pathology

These options were chosen carefully to include the most likely and most commonly seen radiographic findings. Because the study was

retrospective, there was a definitive diagnosis and treatment known for each case but not disclosed to the examiners. The definitive clinical diagnosis was referred to as the “gold standard” because it was the final diagnosis determined by the clinician during treatment. The definitive diagnosis was documented clinically either on access (perforation and internal/external resorption) or through surgical exploration in cases of suspected vertical root fracture or invasive cervical resorption. In cases in which more than 1 preoperative diagnosis was considered possible, the evaluator was asked to select a diagnosis based on the most significant finding.

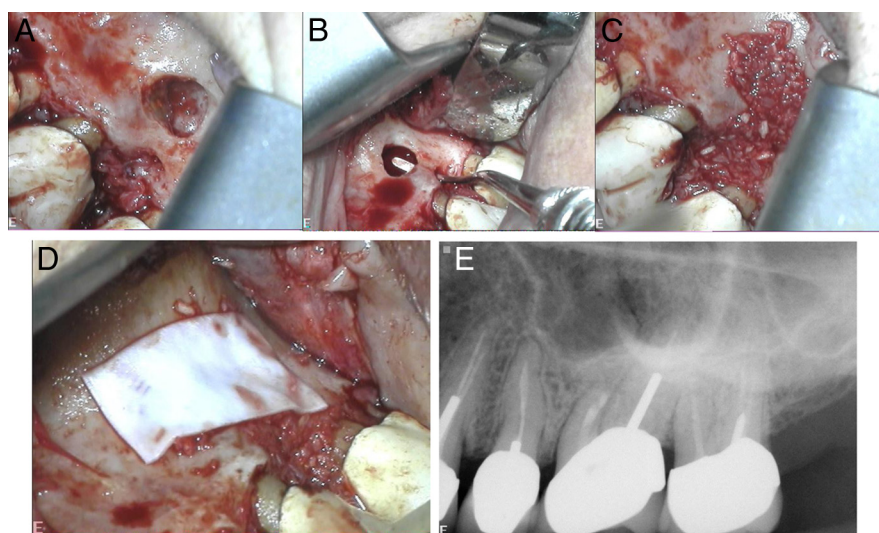


Figure 5. Case 3 continued: (A) A clinical picture after flap reflection showing both crestal and periapical lesions. (B) Communication between both defects. (C) Both defects grafted with an EnCore combination allograft (Osteogenics Biomedical, Lubbock, TX). (D) CopiOs pericardium membrane (Zimmer, Warsaw, IN). (E) An immediate postoperative radiograph.

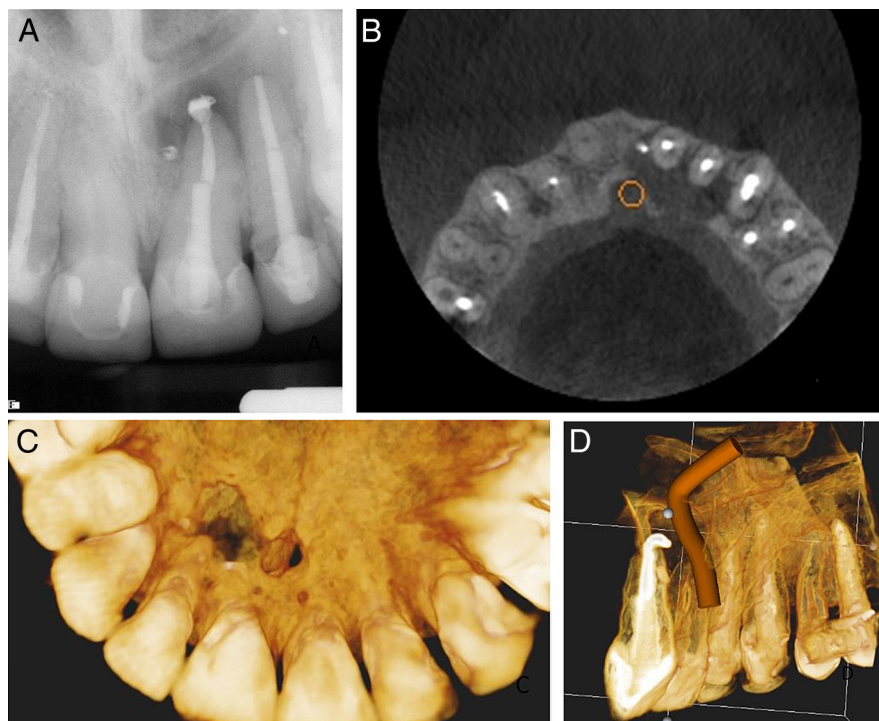


Figure 6. Case 4: (A) A periapical radiograph of the maxillary anterior region showing a periapical lesion associated with tooth #9. (B) An axial view showing the extent of the lesion, palatal plate perforation, and relationship of the nasopalatine neurovascular bundle to the periapical lesion. (C) A palatal view of the 3D reconstruction showing perforation of the palatal plate. (D) A 3D reconstruction showing the nasopalatine bundle.

Radiographic Treatment Plan

In addition to the radiographic diagnosis, the evaluators were asked to select the most appropriate treatment plan from the following choices:

1. Initial nonsurgical root canal treatment
2. Retreatment root canal therapy
3. Orthograde perforation repair and root canal treatment
4. Endodontic surgery (may include perforation repair, apical root-end surgery, and/or biopsy)
5. Extraction

The “no treatment” option was not included in the treatment plan list because all 30 cases had 1 of the 5 treatment options performed. If an examiner circled “No radiographic pathology” for their radiographic diagnosis, by default “Initial non-surgical root canal treatment” was circled from the list of treatment options (assuming the case did not have a previous root canal filling). In cases that included 2 or more of the previously described choices, the examiners were asked to circle the choice that was most significantly related to treatment success. For example, if the tooth required a perforation repair as well as nonsurgical root canal retreatment, the examiner would circle perforation repair. Similarly, if the tooth required root canal retreatment followed by surgery, the examiner was advised to circle surgery.

CBVT Diagnosis and Treatment Plan

Two weeks after evaluation of the digital periapical radiographs, the 3 evaluators reviewed 30 CBVT scans of the same teeth. The cases were organized and presented in random order. The images were of the same teeth as the periapical radiographs. Each examiner was allowed to adjust and move through the volumes freely without a time

limit. The 3 evaluators completed the radiographic diagnosis and preliminary treatment plan for the 30 scans as previously performed for the periapical radiographs.

Data Analysis and Comparison of Treatment Plans

The diagnosis and treatment plan recommendations from both imaging modalities were compared to determine if there was a significant difference. The preoperative diagnosis derived from each of the 2 imaging modalities was also compared with the gold standard diagnosis. The examiners’ diagnoses derived from the periapical radiographs were compared with their diagnosis after viewing the CBVT scans. Statistical analysis was performed using Microsoft Excel (Microsoft Corp, Redmond, WA) 2008 software and SPSS software (IBM, Armonk, NY).

The list of periapical radiograph and CBVT diagnoses were compared with the gold standard for each examiner. The number of cases matching the gold standard was compared for the periapical radiographs and CBVT images. A chi-square test was performed to determine if there was a significant change in treatment planning between periapical radiographs and CBVT scans for each examiner.

Results

Comparison between Gold Standard and Radiographs

The periapical radiographic diagnosis and the gold standard were compared. The radiographic diagnosis was a match with the gold standard in 11 of 30 cases (36.6%) for examiner 1, 11 of 30 cases (36.6%) for examiner 2, and 12 of 30 cases (40%) for examiner 3.

Comparison between Gold Standard and CBVT Scans

The CBVT diagnosis matched the gold standard in 25 of 30 cases (83.3%) for examiner 1, 25 of 30 cases (83.3%) for examiner 2, and 23 of 30 cases (76.6%) for examiner 3.

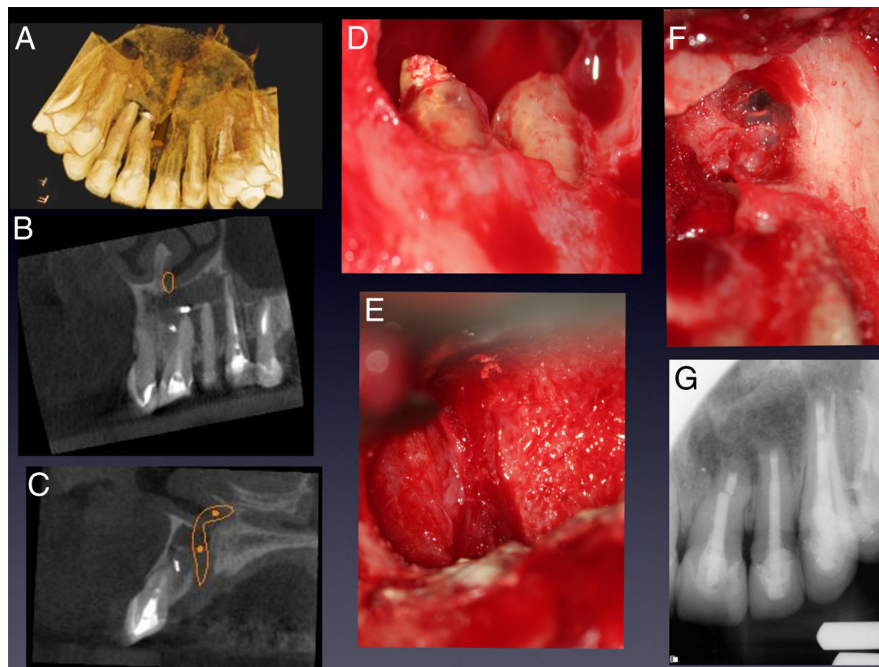


Figure 7. Case 4 continued: (A) A palatal view CBVT reconstruction showing the exit of the nasopalatine bundle from the incisive canal. (B) The sagittal view showing periapical radiolucency involving teeth #9, 10, and 11. (C) The coronal view of the exit of the nasopalatine bundle from the incisive canal. (D) A periapical defect after degranulation showing the apices of teeth #9 and 10 before resection. (E) A clinical picture of the nasopalatine duct intact after degranulation. (F) The lateral wall of the maxillary sinus distal to tooth #11. (G) An immediate postoperative radiograph after grafting the through-and-through defect with Puros allograft (Zimmer Dental, Warsaw, IN) material and, CopiOs membrane.

Comparison between Radiographs and CBVT Scans with Gold Standard Diagnosis

A higher number of cases from the CBVT group were in agreement with the gold standard compared with the periapical radiographic diagnosis group. A difference was found between the 2 imaging modalities in 14 of 30 cases (46.6%) for examiner 1, 14 of 30 cases (46.6%) for examiner 2, and 12 of 30 cases (40%) for examiner 3.

Treatment Plan Changes between Radiographs and CBVT Imaging

Each examiner made a preliminary treatment plan based on the periapical radiographic diagnosis and CBVT diagnosis. Thirty treatment plans based on the radiographs were compared with the 30 treatment plans based on the CBVT images (Fig. 4). A change in the examiner's treatment plan between the 2 imaging modalities was recorded in 19 of 30 cases for examiner 1 (63.3%), 17 of 30 cases for examiner 2 (56.6%), and 20 of 30 cases for examiner 3 (66.7%).

Statistical Analysis

There was a significant change in the treatment plan between the periapical radiographs and CBVT volumes for examiner 1 ($P = .001$), examiner 2 ($P = .012$), and examiner 3 ($P = .008$). We reject the null hypothesis that a preoperative CBVT image does not significantly change a proposed treatment plan when compared with periapical radiographs only.

Discussion

The problem of incorrect, delayed, or inadequate endodontic diagnosis and treatment planning places the patient at risk and could result in unnecessary or inappropriate endodontic treatment.

Two-dimensional periapical radiographs reveal a limited amount of information that may lead the clinician to misdiagnose or overlook potential pathology. Endodontic treatment planning based on conventional 2D periapical radiographs alone may be inadequate in some cases. This retrospective clinical study was designed to compare the relative value of 2 imaging modalities (periapical radiographs and CBVT imaging) for diagnosis and treatment planning decisions in challenging cases. Although dental imaging is most certainly an important factor in diagnosis and treatment planning, it must be acknowledged that imaging should always complement the clinical examination. This study did not provide any clinical tests or patient complaint information to specifically isolate the interpretation of images from the influence of clinical findings. Other studies have used the same design to eliminate potential bias from the clinical examination information provided to examiners when comparing findings with the gold standard (8).

Implications for Clinical Practice

Under the conditions of this study, CBVT imaging was a more accurate imaging modality for the diagnosis of endodontic pathology when compared with diagnosis using only periapical radiographs. An accurate diagnosis was reached in 36.6%–40% of the cases when using periapical radiographs compared with an accurate diagnosis in 76.6%–83.3% of the cases when using CBVT imaging. The interpretation of periapical radiographs yielded a much lower match to the gold standard diagnosis when compared with diagnosis using CBVT imaging. This high level of misdiagnosis is potentially clinically relevant, especially in cases of invasive cervical root resorption and vertical root fracture in which a lack of early detection could lead to unsuccessful treatment and tooth loss. CBVT imaging clearly identifies important anatomic structures and aids in surgical treatment planning as well as nonsurgical repair of perforations and resorptive

defects. This study also shows that the treatment plan may be directly influenced by information gained from a CBVT scan. In this study, the examiners altered their treatment plan after viewing the CBVT scan in 62.2% of the cases overall (range 56.6%–66.7%). This high number indicates that CBVT imaging had a significant influence on the examiners' treatment plan. It can be concluded that a preoperative CBVT image provides more diagnostic information than a preoperative periapical radiograph and that this information can directly influence a clinician's treatment plan. Although imaging is a very important diagnostic tool in endodontics, it should always be used as an adjunct to the clinical examination. The addition of subjective and objective clinical findings to CBVT imaging should allow for an even more accurate clinical diagnosis and appropriate treatment plan. Future studies may explore the potential added value of CBVT scanning when provided along with relevant history and clinical findings.

Acknowledgments

Supported in part by grants from the American Association of Endodontists Foundation and the Edgar D. Coolidge Endodontic Study Club.

The authors deny any conflicts of interest related to this study.

References

1. Reit C, Petersson K. Diagnosis of pulpal and periradicular disease. In: Bergenholtz G, Horsted-Bindsvlev P, Reit C, eds. *Textbook of Endodontology*, 2nd ed. UK: Wiley-Blackwell; 2010:235–53.
2. Kundel HL, Revesz G. Lesion conspicuity, structured noise, and film reader error. *AJR Am J Roentgenol* 1976;126:1233–8.
3. Maini A, Durning P, Drage N. Resorption: within or without? The benefit of cone-beam computed tomography when diagnosing a case of an internal/external resorption defect. *Br Dent J* 2008;204:135–7.
4. Patel S, Ricucci D, Durak C, Tay F. Internal root resorption: a review. *J Endod* 2010;36:1107–21.
5. Estrela C, Bueno MR, De Alencar AH, et al. Method to evaluate inflammatory root resorption by using cone beam computed tomography. *J Endod* 2009;35:1491–7.
6. Hassan B, Metska ME, Ozok AR, et al. Detection of vertical root fractures in endodontically treated teeth by a cone beam computed tomography scan. *J Endod* 2009;35:719–22.
7. Bernardes RA, de Moraes IG, Húngaro Duarte MA, et al. Use of cone-beam volumetric tomography in the diagnosis of root fractures. *Oral Surg Oral Med Oral Pathol Oral Radiol Endod* 2009;108:270–7.
8. Edlund M, Nair MK, Nair UP. Detection of vertical root fractures by using cone-beam computed tomography: a clinical study. *J Endod* 2011;37:768–72.
9. Fayad MI, Ashkenaz PJ, Johnson BR. Different representations of vertical root fractures detected by cone-beam volumetric tomography: a case series report. *J Endod* 2012;38:1435–42.
10. Michetti J, Maret D, Mallet JP, Diemer F. Validation of cone beam computed tomography as a tool to explore root canal anatomy. *J Endod* 2010;36:1187–90.
11. Liang YH, Li G, Wesselink PR, Wu MK. Endodontic outcome predictors identified with periapical radiographs and cone-beam computed tomography scans. *J Endod* 2011;37:326–31.
12. de Paula-Silva FW, Wu MK, Leonardo MR, et al. Accuracy of periapical radiography and cone-beam computed tomography scans in diagnosing apical periodontitis using histopathological findings as a gold standard. *J Endod* 2009;35:1009–12.
13. Velvart P, Hecker H, Tillinger G. Detection of the apical lesion and the mandibular canal in conventional radiography and computed tomography. *Oral Surg Oral Med Oral Pathol Oral Radiol Endod* 2001;92:682–8.
14. Stavropoulos A, Wenzel A. Accuracy of cone beam dental CT, intraoral digital and conventional film radiography for the detection of periapical lesions: an ex vivo study in pig jaws. *Clin Oral Investig* 2007;11:101–6.
15. Nakata K, Naitoh M, Izumi M, et al. Effectiveness of dental computed tomography in diagnostic imaging of periradicular lesion of each root of a multiradical tooth: a case report. *J Endod* 2006;32:583–7.
16. Lofthag-Hansen S, Huuomonen S, Gröndahl K, Gröndahl HG. Limited cone-beam CT and intraoral radiography for the diagnosis of periapical pathology. *Oral Surg Oral Med Oral Pathol Oral Radiol Endod* 2007;103:114–9.
17. Cotton TP, Geisler TM, Holden DT, et al. Endodontic applications of cone-beam volumetric tomography. *J Endod* 2007;33:1121–32.
18. Patel S, Dawood A, Whaites E, Pitt Ford T. New dimensions in endodontic imaging: part 1. Conventional and alternative radiographic systems. *Int Endod J* 2009;42:447–62.
19. Patel S. New dimensions in endodontic imaging: part 2. Cone beam computed tomography. *Int Endod J* 2009;42:463–75.
20. Scarfe WC, Farman AG, Sukovic P. Clinical applications of cone-beam computed tomography in dental practice. *J Can Dent Assoc* 2006;72:75–80.
21. Nair MK, Nair UP. Digital and advanced imaging in endodontics: a review. *J Endod* 2007;33:1–6.
22. Farman AG, Farman TT. A comparison of 18 different x-ray detectors currently used in dentistry. *Oral Surg Oral Med Oral Pathol Oral Radiol Endod* 2005;99:485–9.
23. Farman AG. ALARA still applies. *Oral Surg Oral Med Oral Pathol Oral Radiol Endod* 2005;100:395–7.